White Matter and Visuospatial Processing in Autism: A Constrained Spherical Deconvolution Tractography Study

Jane McGrath, Katherine Johnson, Erik O'Hanlon, Hugh Garavan, Louise Gallagher, and Alexander Leemans

Autism spectrum disorders (ASDs) are associated with a marked disturbance of neural functional connectivity, which may arise from disrupted organization of white matter. The aim of this study was to use constrained spherical deconvolution (CSD)-based tractography to isolate and characterize major intrahemispheric white matter tracts that are important in visuospatial processing. CSD-based tractography avoids a number of critical confounds that are associated with diffusion tensor tractography, and to our knowledge, this is the first time that this advanced diffusion tractography method has been used in autism research. Twenty-five participants with ASD and aged 25, intelligence quotient-matched controls completed a high angular resolution diffusion imaging scan. The inferior fronto-occipital fasciculus (IFOF) and arcuate fasciculus were isolated using CSD-based tractography. Quantitative diffusion measures of white matter microstructural organization were compared between groups and associated with visuospatial processing performance. Significant alteration of white matter organization was present in the right IFOF in individuals with ASD. In addition, poorer visuospatial processing was associated in individuals with ASD with disrupted white matter in the right IFOF. Using a novel, advanced tractography method to isolate major intrahemispheric white matter tracts in autism, this research has demonstrated that there are significant alterations in the microstructural organization of white matter in the right IFOF in ASD. This alteration was associated with poorer visuospatial processing performance in the ASD group. This study provides an insight into structural brain abnormalities that may influence atypical visuospatial processing in autism. ***Autism Res*** *2013, 6: 307–319*. © 2013 International Society for Autism Research, Wiley Periodicals, Inc.

Keywords: diffusion MRI; constrained spherical deconvolution; tractography; autism; visuospatial processing; inferior fronto-occipital fasciculus

Introduction

Autism and autism spectrum disorders (ASDs) are associated with a marked disturbance of neural functional connectivity. A growing literature suggests that functional connectivity abnormalities in ASD are widespread, affect multiple cognitive functions and can be characterized by both reduced [e.g. Just, Cherkassky, Keller, & Minshew, 2004] and increased [e.g. Monk et al., 2009] patterns of connectivity. The pathophysiology of this abnormal functional connectivity is poorly understood, but it may arise from disrupted organization of white matter in interhemispheric and intrahemispheric tracts.

Diffusion-weighted (DW) magnetic resonance imaging (MRI) allows for noninvasive, in vivo examination of white matter tissue microstructure in the human brain. There has been a recent explosion of interest in using fiber tracking on DW-MRI data to investigate brain connectivity in both healthy and disordered populations. The diffusion tensor model is currently the most commonly used framework to relate the diffusion signal to the direction of the fibers [Basser, Mattiello, & LeBihan, 1994; Jones & Leemans, 2011; Mori & van Zijl, 2002], and over the past years, a number of studies have used this approach to isolate specific white matter tracts in autism. Quantitative analysis of the diffusion parameters extracted from these tracts have indicated disruption of white matter organization in major tracts including the corpus callosum (CC) [Hong et al., 2011; Jeong, Kumar, Sundaram, Chugani, & Chugani, 2011; Kumar et al., 2010; Lo et al., 2011; Thomas, Humphreys, Jung, Minshew, & Behrmann, 2011; Weinstein et al., 2011; Wolff et al., 2012], uncinate fasciculus (UF) [Jeong et al., 2011; Kumar et al., 2010; Lo et al., 2011; Poustka et al., 2011; Pugliese et al., 2009; Thomas et al., 2011; Wolff et al., 2012], cingulum [Kumar et al., 2010; Lo et al.,

From the Department of Psychiatry, Trinity Centre for Health Sciences, St James's Hospital, Dublin, Ireland (J.M., K.J., L.G.); Psychological Sciences, University of Melbourne, Parkville, Victoria, Australia (K.J.); Department of Psychiatry, Royal College of Surgeons in Ireland, Beaumont Hospital, Dublin, Ireland (E.O.); School of Psychology and Institute of Neuroscience, Trinity College Dublin, Dublin, Ireland (H.G.); Departments of Psychiatry and Psychology, University of Vermont, Burlington, Vermont, USA (H.G.); Image Sciences Institute, University Medical Center Utrecht, Utrecht, The Netherlands (A.L.)

Received September 7, 2012; accepted for publication February 15, 2013

Address for correspondence and reprints: Jane McGrath, Department of Psychiatry, Trinity Centre for Health Sciences, St James's Hospital, Dublin 8, Ireland. E-mail: jane.mcgrath@tcd.ie

Published online 18 March 2013 in Wiley Online Library (wileyonlinelibrary.com)
DOI: 10.1002/aur.1290

2011; Pugliese et al., 2009; Weinstein et al., 2011], arcuate fasciculus (AF) [Fletcher et al., 2010; Jeong et al., 2011; Kumar et al., 2010; Lo et al., 2011; Wan, Marchina, Norton, & Schlaug, 2012], superior longitudinal fasciculus (SLF) [Verhoeven et al., 2011] and inferior longitudinal fasciculus (ILF) [Pugliese et al., 2009; Thomas et al., 2011; Wolff et al., 2012], but the results from these studies are mixed, and no clear picture of the underlying microstructural pathology has emerged. For example, abnormal microstructural organization of white matter in the CC has been reported in a number of studies; an increase in fractional anisotropy (FA) has been reported in very young children with ASD [Weinstein et al., 2011; Wolff et al., 2012] and a reduction in FA has been reported in older children [Kumar et al., 2010; Lo et al., 2011], yet other studies of both children and adults did not find any differences in FA [Poustka et al., 2011; Thomas et al., 2011]. In studies that have examined microstructural organization of the UF, reduced FA has been reported in two studies [Kumar et al., 2010; Poustka et al., 2011], whereas two other studies have found no difference in the FA of this tract (in infants aged 12–24 months) [Wolff et al., 2012] or in adults with ASD [Thomas et al., 2011]. Studies investigating the cingulum [Kumar et al., 2010; Lo et al., 2011; Pugliese et al., 2009; Weinstein et al., 2011], ILF [Pugliese et al., 2009; Thomas et al., 2011; Wolff et al., 2012], inferior fronto-occipital fasciculus (IFOF) [Kumar et al., 2010; Pugliese et al., 2009; Thomas et al., 2011] and AF [Fletcher et al., 2010; Jeong et al., 2011; Kumar et al., 2010; Lo et al., 2011] have also reported conflicting results.

In voxels containing more than one coherently oriented fiber population (e.g. in "crossing fibers" configurations), it is well recognized that the diffusion tensor model is inadequate [Alexander, Barker, & Arridge, 2002; Frank, 2002; Tournier, Mori, & Leemans, 2011; Wedeen et al., 2000, 2008]. Such voxels containing multiple fiber populations occur frequently throughout the white matter because of partial volume effects between adjacent tracts or the interwoven nature of certain fiber pathways [Tournier et al., 2008; Vos, Jones, Viergever, & Leemans, 2011; Wedeen et al., 2012]. A recent paper revealed the scale of this problem to be much more significant than previously thought; in a study that was specifically designed to investigate the extent of crossing fibers in white matter, the proportion of white matter voxels containing crossing fibers was estimated to be at least 90% [Jeurissen, Leemans, Tournier, Jones, & Sijbers, 2012]. This value is far higher than the 33% that had previously been reported [Behrens, Berg, Jbabdi, Rushworth, & Woolrich, 2007], and has major implications for diffusion tensor tractography and tensor-derived scalar measures [Jeurissen et al., 2012; Vos, Jones, Jeurissen, Viergever, & Leemans, 2012; Wheeler-Kingshott & Cercignani, 2009]. In regions of complex fiber architecture, tensor-derived measures such as FA and mean diffusivity (MD) are unreliable [Jones & Cercignani, 2010; Vos et al., 2012], and the interpretation of these measures can be ambiguous [Jeurissen et al., 2012]. For instance, in a region where two fibers are crossing at 90°, FA will be lower relative to FA in a single-fiber population. If one of these two crossing fibers disintegrates as a result of some pathological process, the FA will increase in this region. A similar observation has been noted in Douaud et al. [2011]. Although Diffusion Tensor Imaging (DTI) metrics are not very *specific* about the type of white matter change occurring, they can still be very *sensitive* to genuine changes in microstructural organization of white matter. Recent work has also shown that—compared with conventionally applied DTI-based tractography—combining CSD-based tractography with DTI metrics can increase the sensitivity to detect functionally significant white matter abnormalities in tracts with complex white matter architecture [Reijmer et al., 2012].

In order to reduce the ambiguity about the biological interpretation of FA changes, alternative measures of diffusion anisotropy are often measured in conjunction with FA. One example of such alternative tensor-based metrics are the Westin measures of linear diffusion coefficient (CL) and planar diffusion coefficient (CP). Although these measures of CL and CP are indeed still based on the eigenvalues, they can describe the geometrical shape of the diffusion tensor and, therefore, can provide a more meaningful interpretation of microstructural changes that are occurring in the ASD group compared with the FA [Westin et al., 2002]. A high value of CL implies that there is only one dominant fiber orientation within a voxel [Vos et al., 2012], and a high value of CP indicates the presence of crossing fiber configurations [Vos et al., 2012].

Perhaps a more important limitation of the diffusion tensor model that has been highlighted by the work of Jeurissen et al. [2012] is that in voxels with crossing fibers, the diffusion tensor model cannot adequately describe fiber orientation, thus the underlying orientation of the white matter tracts cannot be reliably estimated. Therefore, fiber-tracking algorithms that rely on the diffusion tensor will produce unreliable results in regions containing multiple fiber orientations. This may result in a failure to identify white matter connections in an accurate way—for example, where the tracking algorithm terminates prematurely [Behrens et al., 2007; Jeurissen, Leemans, Jones, Tournier, & Sijbers, 2011]. Alternatively, it may lead to the isolation of white matter connections that do not really exist—where tracking switches to an unrelated adjacent tract [Jeurissen et al., 2011; Pierpaoli et al., 2001].

The unexpectedly high prevalence of crossing fibers in white matter is likely to have significant implications for diffusion tensor imaging in clinical research. Specifically

in ASD, 15 of the 16 previous fiber tractography studies have used diffusion tensor-based tractography methods [Catani et al., 2008; Conturo et al., 2008; Fletcher et al., 2010; Hong et al., 2011; Jeong et al., 2011; Jou et al., 2011; Kumar et al., 2010; Langen et al., 2012; Poustka et al., 2011; Pugliese et al., 2009; Sahyoun, Belliveau, Soulieres, Schwartz, & Mody, 2010; Thomas et al., 2011; Wan et al., 2012; Weinstein et al., 2011; Wolff et al., 2012], while one study used diffusion spectrum imaging [Lo et al., 2011]. Given the inadequacies of the diffusion tensor model in regions of crossing fibers, it may well be possible that the tensor-derived scalar measures and tractography results that have been reported in these studies are unreliable. Such a lack of reliability could account for the inconsistent results from diffusion tensor tractography studies in ASD.

A number of more complex diffusion reconstruction schemes have been proposed to overcome the limitations associated with the DTI model [see Tournier et al., 2011 for an overview]. One such approach is that of constrained spherical deconvolution (CSD), a method that allows reliable estimation of one or more fiber orientations in the presence of intravoxel orientational heterogeneity [Tournier, Calamante, & Connelly, 2007; Tournier, Calamante, Gadian, & Connelly, 2004; Tournier et al., 2008]. The CSD technique is computationally simple and very fast, the diffusion data for CSD can be acquired with clinically feasible settings, no a priori information is needed regarding the number of distinct fiber orientations, fiber orientations are estimated directly, and it is not dependant on any assumed model of diffusion [Tournier et al., 2004]. Importantly, this approach overcomes partial volume effects associated with diffusion tensor imaging, allows reliable estimation of diffusion measures, permits fiber tracking through regions of crossing fibers [Tournier et al., 2008], and has recently shown promising results in other clinical applications [Metzler-Baddeley et al., 2012; Reijmer et al., 2012].

To look for evidence of altered structural organization of key white matter tracts in autism, two major intrahemispheric association tracts (IFOF and AF) were examined using a CSD-based tractography approach in this study. These white matter tracts were selected for a number of reasons. (a) The IFOF and the AF link frontal and posterior brain regions that have repeatedly shown abnormal functional connectivity in autism [e.g. Just, Cherkassky, Keller, Kana, & Minshew, 2007; Just et al., 2004]. Knowledge of white matter microstructure in these fronto-posterior tracts is crucial to understanding the anatomical correlates of abnormal fronto-posterior functional connectivity in autism, but to date, white matter organization in these tracts is not well understood. Results from the few studies that have examined these tracts do not provide a clear picture of underlying pathology. Reduced left lateralization [Fletcher et al., 2010; Lo et al., 2011], increased curvature [Jeong et al., 2011] and reduced FA [Kumar et al., 2010] of the AF have been reported in individuals with autism. Relative to controls, increased left lateralization of volume was reported in the IFOF in adults with ASD [Thomas et al., 2011]; however, two other studies did not observe any abnormalities of this tract [Kumar et al., 2010; Pugliese et al., 2009]. There is emerging interest in hemispheric asymmetry in ASD, and with tractography this can be investigated in great detail. (b) The AF in the right hemisphere is known to be involved in visuospatial processing [Doricchi, Thiebaut de Schotten, Tomaiuolo, & Bartolomeo, 2008; Thiebaut de Schotten et al., 2008], and the IFOF is also thought to play a role in visual processing [Catani & Thiebaut de Schotten, 2008; Fox, Iaria, & Barton, 2008; Rudrauf, Mehta, & Grabowski, 2008]. The functional role of these tracts in visuospatial processing is of particular relevance to this study as behavioral data from a visuospatial processing task were available on 42 of the 50 study participants who completed the diffusion MRI scan for this study, thus allowing for an investigation of relationships between brain structure (diffusion measures) and visuospatial processing performance. (c) The IFOF and AF were also implicated by a functional connectivity analysis of functional MRI data that was previously collected from participants in this study during a visuospatial processing task. Brain regions that showed abnormal functional connectivity in autism during visuospatial processing were in close proximity to the IFOF and AF [McGrath et al., 2012].

Atypical visuospatial processing is commonly described in autism spectrum disorders. In brief, enhanced visuospatial processing in ASD has been described in behavioral studies during a variety of cognitive tasks [see McGrath et al., 2012 for a review]. A number of recent neuroimaging studies have not found evidence of superior visuospatial performance in ASD; however, they have revealed that brain activity and connectivity differs markedly between ASD and control groups [Damarla et al., 2010; Lee et al., 2007; Manjaly et al., 2007]. Recent work from our group used functional connectivity MRI to investigate the neural correlates of visuospatial processing during a mental rotation task, whereby two rotated stimuli were judged to be the same ("same" trials) or mirror imaged ("mirror" trials). Results of this study indicated that there was a relative advantage of mental rotation in the ASD group that was associated with aberrant functional connectivity. Long-range fronto-posterior underconnectivity and short-range intraoccipital overconnectivity were reported in this study. These findings are in keeping with two neuropsychological theories of autism that offer an explanation for superior visuospatial processing in the condition. The enhanced perceptual functioning theory [Mottron, Dawson, Soulières, Hubert, & Burack, 2006] suggests that there is enhanced

functioning of low-level visual cortical regions and superior locally oriented processing in ASD that result in enhanced visuospatial performance [e.g. Caron et al., 2006; Soulieres, Zeffiro, Girard, & Mottron, 2011], while the weak central coherence theory holds that there is superior local processing in ASD possibly combined with a deficit in the global integration of information [Happe & Frith, 2006].

The main aim of this study was to isolate and characterize major intrahemispheric white matter tracts in autism using CSD-based fiber tractography in order to investigate white matter organization in specific tracts that are important in visuospatial processing. CSD-based tractography avoids a number of critical confounds that are associated with diffusion tensor tractography, and to our knowledge, this is the first time that this advanced diffusion tractography method has been used in autism research. Based on the limited literature, we hypothesized that (a) there would be significant differences in white matter microstructure between individuals with ASD and healthy controls; specifically, that there would be reduced FA and reduced left lateralization of the AF, and increased left lateralization of microstructural organization of the IFOF. We hypothesized (b) that the microstructural properties of the specific tracts involved in visuospatial processing would be associated with visuospatial processing performance in ASD.

Methods and Materials

Participants

Participants with ASD were recruited from an existing autism genetics sample at the Department of Psychiatry, Trinity College Dublin, and through additional recruitment from local schools and child and adolescent mental health services. The diagnosis of ASD was established using two structured research diagnostic tools, the Autism Diagnostic Interview-Revised [Lord, Rutter, & Le Couteur, 1994] and the Autism Diagnostic Observation Schedule-Generic [Lord et al., 2000], by trained research reliable administrators. All participants met criteria for a diagnosis of ASD. Control participants were recruited from the community and were selected to match the ASD participants on age, handedness, gender, race and intelligence quotient (IQ; full-scale IQ was estimated based on four subscales of the Wechsler Intelligence Scale for Children (WISC)/Wechsler Adult Intelligence Scale (WAIS) (WISC-IV UK [Wechsler, 2004] and WAIS-III [Wechsler, 1997])).

Exclusion criteria included known causes for autism, e.g. tuberous sclerosis/fragile X syndrome, current/past neurological or psychiatric conditions, serious head injuries, MR contraindications, below-average intelligence (full-scale IQ < 80) and current use of psychoactive medication. Additional exclusion criteria for controls included history of developmental delay or first-degree relatives with ASD. The study was approved by the Irish Health Services Executive Linn Dara/Beechpark Research Ethics committee and by the Ethics Committee of the School of Psychology in Trinity College Dublin. Participants were provided with written information about the study and a recording of the noise of the scanner for familiarization. Prescanning visits to the MRI simulator were also offered. Written informed consent was obtained from parents and assent or consent from participants prior to scanning as appropriate. Demographics of participants are detailed in Table 1.

Table 1. Demographics of participants

	Control	ASD	*P*-value
Number	25	25	
Gender	25 male, 0 female	25 male, 0 female	
Age mean (SD)	17.37 (2.67)	17.28 (2.87)	0.94
IQ Mean (SD)	110.72 (16.02)	106.84 (14.54)	0.37
Handedness	All right handed	All right handed	
Medication	None	None	

ASD, autism spectrum disorder; SD, standard deviation; IQ, intelligence quotient.

Data Acquisition/Preprocessing

Whole-brain high angular resolution diffusion imaging (HARDI) data were acquired on a Philips Intera Achieva 3.0 Tesla MR system (Philips, Best, Netherlands) equipped with an eight-channel head coil. A parallel sensitivity encoding (SENSE) approach [Pruessmann, Weiger, Scheidegger, & Boesiger, 1999] with a reduction factor of 2 was utilized for all DW image acquisitions. Single-shot spin echo-planar imaging was used to acquire DW data using the following parameters [Jones & Leemans, 2011]: echo time (TE) 79 msec, repetition time (TR) 20,122 msec, field of view 248 mm, matrix 128×128, isotropic voxel resolution $2 \times 2 \times 2$ mm and 65 slices with 2 mm thickness with no gap between slices. Diffusion gradients were applied in 61 isotropically distributed orientations with $b = 1500$ s/mm^2, and also four images with $b = 0$ s/mm^2 were acquired. Total scan time was 24.3 min.

Preprocessing and tractography analyses were performed with the diffusion MR toolbox *ExploreDTI* (http://www.ExploreDTI.com) [Leemans, Jeurissen, Sijbers, & Jones, 2009]. Each DW-MRI dataset was corrected for eddy current-induced geometric distortions and subject motion by realigning all DW images (to the $b = 0$ images using *Elastix* [Klein, Staring, Murphy, Viergever, & Pluim, 2010], with an affine coregistration technique (with 12 degrees of freedom) and mutual information as the cost function [Pluim, Maintz, & Viergever, 2003]. In this

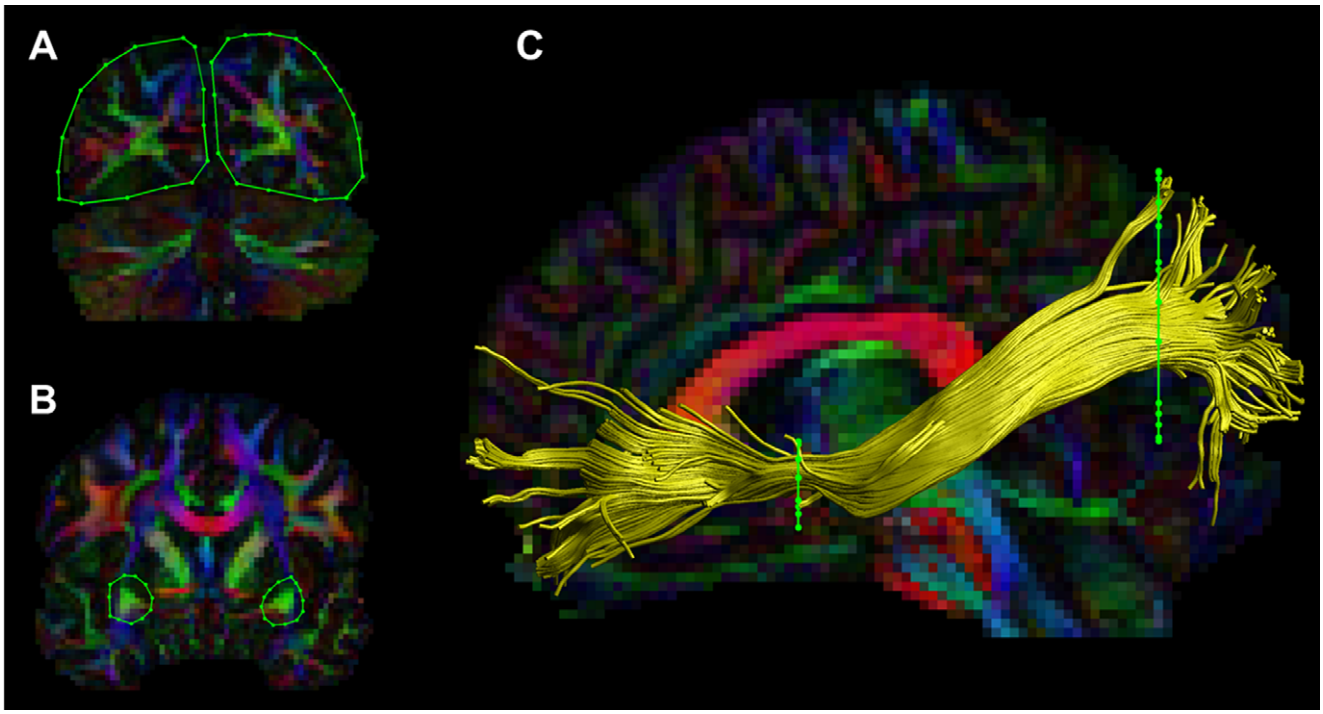

Figure 1. Illustration of the protocol used for extraction of the inferior fronto-occipital fasciculus (IFOF). (**A**) Green lines demarcate "AND" region of interest (ROI)_1 (the term "AND" indicates that fibers must pass through this ROI) for the left and right IFOF; (**B**) "AND" ROI_2 for the left and right IFOF; (**C**) sagittal view of left IFOF and ROI_1 and ROI_2; green vertical lines show the positions of ROI_1 and ROI_2 in the sagittal plane.

procedure, the required reorientation of the B-matrix was performed [Leemans & Jones, 2009], and the tensor model was fitted to the data using the RESTORE (robust estimation of tensors by outlier rejection) approach [Chang, Jones, & Pierpaoli, 2005], which uses a process of iteratively reweighted least-square regression for outlier identification and subsequent removal, thus minimizing estimation errors originating from gross signal artifacts (e.g. cardiac pulsation and subject motion).

CSD Tractography

White matter tracts of the IFOF and AF were reconstructed using CSD-based tractography [Jeurissen et al., 2011]. In summary, this tractography algorithm consists of the following steps: (a) CSD was used to extract the fiber orientation distribution (FOD) from the DW signal in each voxel [Tournier et al., 2007]; (b) seed points were defined on a uniform $2 \times 2 \times 2$ mm^3 grid to cover the entire brain; (c) for each step during tract propagation, the FOD peak direction that was closest to the previous stepping direction is extracted; (d) the trajectory is advanced with a fixed step size (1 mm) along the peak direction obtained with (c). Tracking ends when the FOD peak magnitude is beneath a fixed threshold (i.e. 0.1), or when a maximum angle (30°) is exceeded. Subsequently, from this whole-brain tractography result, the IFOF and AF pathways are selected by defining regions of interest (ROIs; see next section).

Tract Extraction Protocols

A multiple ROI approach was employed to isolate the fibers in the tracts of interest. This approach has been shown to ensure robust recovery of the major fiber tracts in the human brain [Mori et al., 2002; Wakana et al., 2007]. To ensure consistency in extracting the tracts across subjects, all tracts of interest were extracted and quantified in native space by the first author (J. M. G.) using specific protocols.

IFOF. The IFOF is a long white matter association tract that links the occipital lobe and the orbitofrontal cortex. Two "AND" ROIs—the term "AND" indicates that fibers must pass through this ROI—were defined to dissect the fibers of the left IFOF and the right IFOF (see Fig. 1). ROI_1 was drawn around the occipital lobe on a coronal slice at the midpoint between the posterior edge of the cingulum and the posterior edge of the parieto-occipital sulcus. The second ROI was drawn around the IFOF (identified as an intense green circular tract in Fig. 1) on a coronal slice in the frontal lobe at the location where

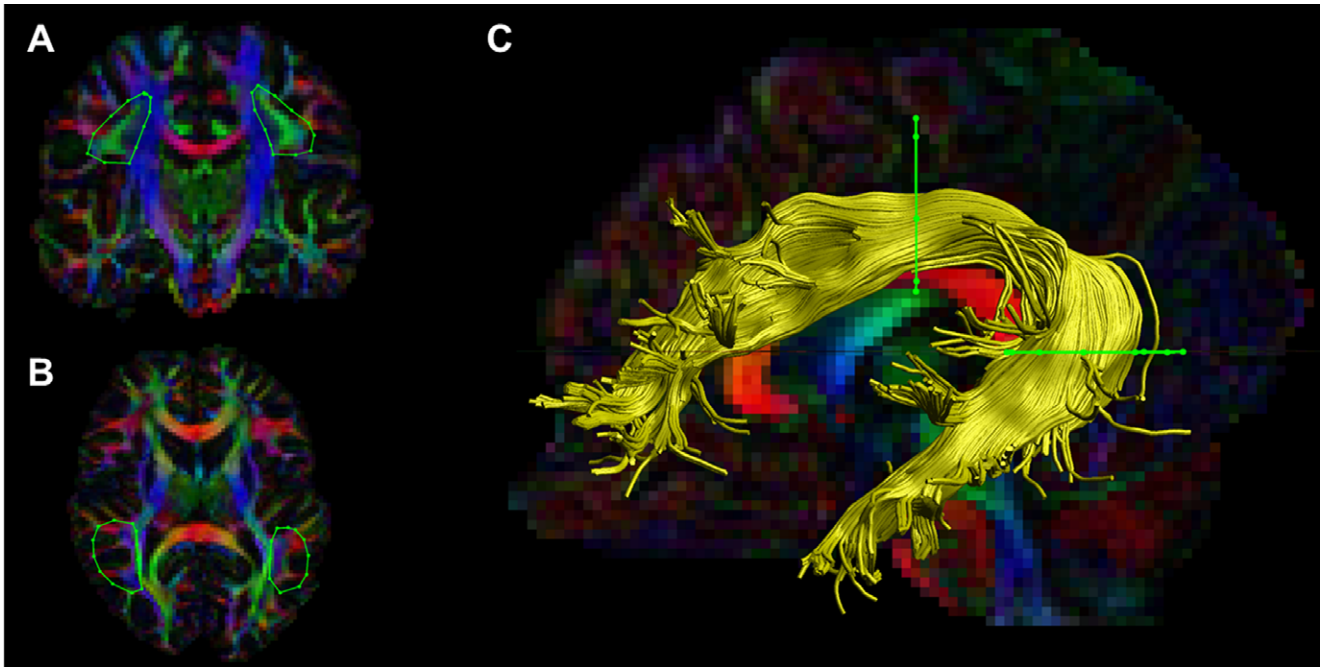

Figure 2. Illustration of the protocol used for extraction of the arcuate fasciculus (AF). (**A**) Green lines demarcate "AND" region of interest (ROI)_1 for the left and right AF on a coronal slice; (**B**) "AND" ROI_2 for the left and right AF on an axial slice; (**C**) sagittal view of left AF and ROI_1 and ROI_2; green vertical and horizonal line show positions of ROI_1 and ROI_2 in the sagittal plane.

frontal and temporal lobes are separated. The tractography algorithm isolated all tracts that passed through both ROI_1 and ROI_2.

AF. The AF is a white matter association tract that is composed of long and short fibers linking the perisylvian cortex of frontal, parietal and temporal lobes. It comprises the temporal part of the SLF. Two "AND" ROIs were defined to isolate the left and the right AF (~~59~~) (see Fig. 2). ROI_1 was drawn on a coronal slice at the level of the middle of the posterior limb of the internal capsule. This ROI was drawn around the core of the SLF (identified as an intense green tract with a triangular shape in Fig. 2) and all branches coming out from this core. ROI_2 was drawn on an axial slice at the level of the inferior part of the splenium around projections lateral to the sagittal stratum. The tractography algorithm isolated all tracts that passed through both these ROIs. All isolated tracts were examined visually and "NOT" ROIs were used to exclude any spurious tracts, for example, removing tracts that crossed into the other hemisphere, or tracts that deviated completely from the main body of the tract.

Dependant Measures

For each tract in each participant, FA and the Westin measures of CL and CP [Westin et al., 2002] were computed from the tracts. FA was the predominant measure of interest as it is the most widely used measure in the literature and shows high sensitivity. The Westin measures of CL and CP are alternative measures of diffusion anisotropy that were used to provide a more specific interpretation of the FA changes.

Statistical Analysis

Statistical comparisons of the data were performed using PASW (SPSS) software version 18 (SPSS Inc., Chicago, IL, USA). For all analyses, the level of statistical significance was defined as $P < 0.05$ (two-tailed), and Bonferroni corrections were used throughout the analyses. For the IFOF and the AF, univariate analysis of variance (ANOVA) with group (ASD/control) as the between-subjects factor was performed for the dependant measures FA, CP and CL. In addition, a "lateralization index" was calculated using the formula [(Left–Right)/(Left + Right)] for each dependant measure for the IFOF and AF tracts. The purpose of this lateralization index was to derive a summary statistic that quantified the degree of hemispheric asymmetry for each participant. The index values range from +1 to –1 with a positive value indicating greater left hemisphere asymmetry [Thomas et al., 2011]. A univariate ANOVA was subsequently performed to investigate group differences in this lateralization index.

To explore an association between white matter organization and behavioral performance during visuospatial processing, bivariate Pearson correlations are used. More specifically, relationships between diffusion properties

Table 2. The mean, standard deviation (SD) and *P*-values for the microstructural dependant measures (fractional anisotropy (FA), planar diffusion coefficient (CP) and linear diffusion coefficient (CL)) for the arcuate fasciculus (AF) and inferior fronto-occipital fasciculus (IFOF)) in the ASD and control groups

		Right hemisphere				Left hemisphere			
		AF		IFOF		AF		IFOF	
Measure	Group	Mean (SD)	*P*	Mean (SD)	*P*	Mean (SD)	*P*	Mean (SD)	*P*
FA	ASD	0.40 (0.02)	0.76	0.47* (0.02)	**0.02***	0.42 (0.02)	0.85	0.47 (0.02)	0.26
	Control	0.39 (0.01)		0.48* (0.02)		0.43 (0.02)		0.48 (0.02)	
CP	ASD	0.186 (0.017)	0.32	0.170* (0.013)	**0.01***	0.210 (0.015)	0.46	0.162 (0.013)	0.49
	Control	0.190 (0.015)		0.161* (0.014)		0.213 (0.015)		0.165 (0.016)	
CL	ASD	0.361 (0.025)	0.47	0.444* (0.023)	**0.03***	0.371 (0.020)	0.75	0.455 (0.025)	0.49
	Control	0.357 (0.016)		0.463* (0.027)		0.369 (0.022)		0.460 (0.030)	

*Indicates significant between-group differences with $P < 0.05$. Bold text was used to highlight significant findings.
ASD, autism spectrum disorder; SD, standard deviation.

and lateralization measures that showed significant abnormality in the ASD group, on the one hand, and average mean response times during a visuospatial processing task of mental rotation, on the other hand, were examined. The mental rotation task is detailed in McGrath et al. [2012]. The primary correlation analysis is the investigation of the relationship between FA (in tracts showing abnormal FA only) and visuospatial processing speed. Subsequent post hoc exploratory correlation analyses using the CL and the CP are performed as these measures provide more specific information about the type of white matter structural change. Pearson correlation analysis is used as mean response times in this study are normally distributed, as indicated by *P*-values of > 0.05 following Kolmgorov–Smirnov and Shapiro–Wilk tests of normality.

Results

Between-Group Differences in Dependant Measures

In the right IFOF, mean FA was significantly lower in the ASD group; ($F(1,48) = 5.143$, $P < 0.028$, $\eta p2 = 0.097$), mean CL was significantly lower in the ASD group ($F(1,48) = 6.724$, $P < 0.013$, $\eta p2 = 0.123$) and mean CP was significantly higher in the ASD group ($F(1,48) = 5.25$, $P < 0.026$, $\eta p2 = 0.099$). These results indicate that the complexity of the microstructural organization of the right IFOF was increased in the ASD group relative to controls. In the left IFOF and in bilateral AFs, there were no between-group differences in microstructural diffusion measures (see Table 2).

Lateralization Index Analysis

In the IFOF, relative to controls, the ASD group showed significantly greater left lateralization of CL ($F(1, 48) = 4.35$, $P < 0.042$, $\eta p2 = 0.083$) and significantly reduced left lateralization of CP ($F(1, 48) = 5.74$, $P < 0.021$, $\eta p2 = 0.107$; see Table 3).

Table 3. Lateralization indices for the microstructural dependant measures (fractional anisotropy (FA), planar diffusion coefficient (CP) and linear diffusion coefficient (CL)) for the AF and IFOF

		AF		IFOF	
Measure	Group	Mean (SD)	*P*-value	Mean (SD)	*P*-value
FA	ASD	0.0328 (0.021)	0.70	0.0058 (0.020)	0.19
	Control	0.0353 (0.025)		–0.0012 (0.017)	
CP	ASD	0.0612 (0.051)	0.71	–0.0250 (0.048)	**0.02***
	Control	0.0560 (0.040)		0.0100 (0.054)	
CL	ASD	0.0140 (0.031)	0.74	0.0120 (0.026)	**0.04***
	Control	0.0170 (0.028)		–0.0031 (0.024)	

*Indicates significant between-group differences with $P < 0.05$. Bold text was used to highlight significant findings.
ASD, autism spectrum disorder; SD, standard deviation; AF, arcuate fasciculus; IFOF, inferior fronto-occipital fasciculus.

In the AF, there were no between-group differences in lateralization of FA, CP or CL (see Table 3).

Correlation Analysis

To investigate the behavioral ramifications of the altered white matter organization in the ASD group, correlation analysis was used to examine the relationships between visuospatial processing performance and diffusion and lateralization measures that showed significant abnormality in the ASD group. Therefore, the diffusion measures used in correlation analyses included the mean FA, mean CP and mean CL of the right IFOF. The lateralization measures used in correlation analyses included the lateralization indices for ASD and control groups for CL and CP for the IFOF.

Correlation analysis revealed a significant negative correlation between mean response time during the mental rotation task and mean FA in the right IFOF (Pearson

Table 4. Results of bivariate Pearson correlation analyses between mean response time (MRT) during visuospatial processing and all diffusion and lateralization measures showing abnormality in the ASD group

	Behavioral measure MRT		
Diffusion measure	Group	r	*P*
FA right IFOF	ASD	**–0.457***	**0.037***
	Control	0.238	0.298
CP right IFOF	ASD	0.150	0.517
	Control	–0.074	0.749
CL right IFOF	ASD	–0.417	0.060
	Control	0.198	0.389
LI CL	ASD	**0.436***	**0.048***
	Control	–0.290	0.202
LI CP	ASD	–0.181	0.434
	Control	0.130	0.574

*Indicates statistical significance ($P < 0.05$). Bold text was used to highlight significant findings.

LI, lateralization index; r, Pearson correlation coefficient; ASD, autism spectrum disorder; FA, fractional anisotropy; IFOF, inferior fronto-occipital fasciculus; CP, planar diffusion coefficient; CL, linear diffusion coefficient.

correlation (r) = –0.46, $P < 0.037$) in the ASD group. There was no correlation between these variables in the control group. The correlation analyses for mean response time and CL in right IFOF showed a trend toward statistical significance in the ASD group (r = –0.457, $P < 0.060$), whereas the control group showed no such trend (r = 0.198, $P < 0.389$; see Table 4).

Again in the ASD group but not in controls, there was a significant positive correlation between the lateralization index of CL and mean response time (r = 0.44, $P < 0.048$). More specifically, increasing left lateralization of CL is associated with slower mean response times (equating to poorer visuospatial processing) in the ASD group.

Discussion

For the first time in autism research, CSD-based tractography has been used to reconstruct and investigate fiber pathways overcoming a number of significant limitations associated with conventional diffusion tensor-based tractography. The major finding from this work is that there are significant differences in microstructural organization of the IFOF in ASD, which is associated with poorer visuospatial processing performance. This discovery is important as it offers a novel insight into specific neuroanatomical abnormalities that may underpin atypical visuospatial processing in ASD.

The IFOF is a major long-range white matter association tract connecting ipsilateral frontal and occipital lobes and ipsilateral frontal and posterior parietal and temporal lobes [Martino, Brogna, Robles, Vergani, & Duffau, 2010]. The function of the IFOF is poorly understood, but it is thought to play an important role in visual processing, reading, attention, the semantic system and, of particular relevance to autism, in correctly recognizing emotion in faces [Catani & Mesulam, 2008; Doricchi et al., 2008; Epelbaum et al., 2008; Fox et al., 2008; Martino et al., 2010; Philippi, Mehta, Grabowski, Adolphs, & Rudrauf, 2009; Rudrauf et al., 2008]. A finding of reduced structural connectivity in this extensive fronto-posterior tract would be in keeping with the theory of long-range fronto-posterior underconnectivity in autism [Just et al., 2004]. It is perhaps surprising, therefore, that only three tractography studies have examined white matter organization of the IFOF in autism. These three studies used diffusion tensor tractography, an approach with significant limitations that have been outlined in the introduction to this paper. One of these studies reported increased left lateralization of volume in the IFOF in adults with ASD [Thomas et al., 2011], but the two other studies found no abnormalities in this tract in individuals with autism [Kumar et al., 2010; Pugliese et al., 2009]. Results from the current study help to resolve this inconsistency in the literature by finding strong evidence of performance-related deficits using the advanced CSD-based tractography approach.

Significant microstructural abnormalities of the right IFOF were present in the ASD group in this study. Interestingly, it has been reported in a large study of patients with focal brain lesions that damage associated with the right IFOF was associated with significant deficits in facial emotion recognition, with specific deficits recognizing sadness, anger and fear [Philippi et al., 2009]. Impairment of emotion recognition is extensively documented in autism [Harms, Martin, & Wallace, 2010], and the finding of microstructural abnormalities in the right IFOF in ASD is exciting as it offers an insight into white matter abnormalities that may underpin a core deficit in the condition. In this study, relative to controls, participants with ASD had reduced FA, reduced CL and increased CP in this tract. The reduced CL and increased CP indicate that relative to controls, the ASD group had a greater level of complexity (crossing fibers) of white matter in the right IFOF. This information about the complexity of white matter is important, as it has been shown that observed changes in FA may be explained by fiber crossings. For example, in regions of crossing fibers, an increase in FA in one fiber population can result in a decrease in the overall FA [Douaud et al., 2011]. In the current study, knowledge of CL and CP reduces ambiguity about the biological interpretation of the reduced FA.

Correlation analysis revealed an intriguing relationship between white matter organization in the right IFOF and behavioral performance during a visuospatial processing task. In the ASD group (but not controls), there was a

negative correlation between FA in the right IFOF and mean response times during mental rotation, indicating an association between the observed white matter microstructural properties and poorer visuospatial processing. There was also a strong trend ($P < 0.060$) toward a similar negative correlation between mean CL in the right IFOF and mean response times during mental rotation in the ASD group, but not in controls. Taken together, these findings suggest that as the level of white matter coherence in the right IFOF diminishes, there is a detrimental effect on visuospatial processing speed in ASD. These correlations are particularly interesting as they reveal an association between atypical visuospatial function in autism and specific structural brain abnormalities. During the most challenging mental rotation trials, individuals with ASD showed stronger negative connectivity than controls between a number of fronto-posterior regions, indicating an increased level of functional suppression between these regions. This increased suppression may reflect an attempt to reduce "interference" from frontal higher-level regions that are normally required for successful mental rotation [Liu, Cherkassky, Minshew, & Just, 2011]. Such a reduced need for higher-level processing may arise from superior low-level perceptual processing at the level of the early visual cortex [Mottron et al., 2006], and evidence has emerged to suggest that there is increased functional connectivity within the early visual cortex during mental rotation [McGrath et al., 2012]. The reduced microstructural organization of the right IFOF in the ASD group that is reported in the current study may lead to a weakening in the strength of negative functional connectivity (reduction of suppression) between frontal and posterior brain regions in the ASD group. In keeping with the theory of Liu et al. 2011, results from the correlation analysis suggest that strong fronto-posterior suppression is important for successful visuospatial processing in ASD; in the ASD group, reduced microstructural organization of the right IFOF was associated with slower mental rotation. The relationship between visuospatial processing performance and white matter microstructural organization that has been revealed in the current study offers an exciting insight into possible etiological structural abnormalities in ASD. Future work investigating white matter within the early visual cortex is needed to determine whether there are white matter structural changes in ASD that could contribute to enhanced low-level perceptual processing.

A test of the lateralization of DTI measurements in the IFOF showed that there was significantly greater right lateralization of CP and greater left lateralization of CL in the ASD group relative to controls. The right lateralization of CP emerged from a right-sided increase in CP in the ASD group. By contrast, the left lateralization of CL appeared to be driven by the right-sided reduction in these measures in the ASD group relative to controls. No previous study has examined lateralization patterns specifically in the IFOF in autism, but one previous study investigating intrahemispheric lateralization differences in autism reported greater left lateralization of number of streamlines and voxels in three intrahemispheric tracts combined together (IFOF, ILF and UF) in ASD [Thomas et al., 2011]. In relation to visual perception, it is known that the right hemisphere is more sensitive to global information, whereas the left hemisphere is more sensitive to information about local features [Robertson & Ivry, 2000; Yovel, Levy, & Yovel, 2001]. Thomas et al. [2011] speculated that the increased left lateralization of volume in ASD might be the source of the local visual bias that has been reported in individuals with autism [Happe & Frith, 2006], but they did not investigate the relationship between volume lateralization and visuospatial processing in ASD. In this study, increased left lateralization of CL was correlated positively with visuospatial processing speed. At first, this correlation appears to suggest that left lateralization of CL is detrimental to visuospatial processing. The increased left lateralization of CL in this study, however, is driven by the relative reduction in CL in the right IFOF, not by increased structural connectivity (increased CL) in the left hemisphere IFOF. It is possible, therefore, that the local visual bias in autism does not arise from increased structural connectivity within the left hemisphere, but instead results from a compensatory increased use of the unimpaired left hemisphere in the face of right hemisphere white matter dysfunction.

The AF connects the perisylvian cortex of the frontal, parietal and temporal lobes. In the right hemisphere, this tract has a function in visuospatial processing [Doricchi et al., 2008; Thiebaut de Schotten et al., 2008], and the left hemisphere AF has a well-established role in language and praxis. White matter microstructure of the right and left AF did not differ between groups in this study, nor were there between-group differences in lateralization. Previous tractography studies investigating the AF in individuals with ASD have shown reduced FA, increased MD and reduced left lateralization of FA, MD, volume and average fiber length [Fletcher et al., 2010; Kumar et al., 2010; Lo et al., 2011; Wan et al., 2012]. One possible reason for the lack of between-group differences in white matter organization in the AF is the methodology that was used in this study. CSD-based tractography allows full isolation of the frontal projections of the AF. In previous studies, it is possible that where the AF passes through regions of crossing fibers in the frontal lobe, fiber tracking terminated prematurely. This would lead to extraction of diffusion measurements from only a segment of the AF rather than the whole tract. It is also important to note that our study population was verbal, with average or above-average IQ. It is possible that individuals with ASD but normal language function do not have significant disruption of white matter in this tract.

There were a number of limitations of this study. Participants with ASD were limited to male, right-handed individuals with average or above-average IQ. Results are therefore very specific to this group and are not representative for all individuals on the spectrum. Bonferroni corrections were not used in the correlation analyses, but it is important to note that FA was used as the primary diffusion measure in the primary analysis, and subsequent post hoc exploratory correlation analyses were performed in an attempt to increase the specificity of the type of white matter change that was associated with visuospatial processing speed. In addition, this study has only considered tensor-based metrics of FA, CL and CP. Such measures are sensitive to microstructural changes in white matter but lack specificity about the type of change that is occurring. Recent methodological studies have described HARDI-based metrics, such as the apparent fiber density [Dell'Acqua, Simmons, Williams, & Catani, 2012; Raffelt et al., 2012], which are likely to become more widely used in future research and which may provide new insights into white matter pathology in ASD. Finally, this study selected only two intrahemispheric tracts for analysis. These tracts are important in visuospatial processing, and the analysis enabled specific investigation of the relationship between brain white matter structure and visuospatial processing performance in autism. It is however possible that there are white matter abnormalities in other tracts that were not investigated here, and future work using CSD-based tractography should focus on isolation of these tracts to better characterize the white matter deficits in autism.

Conclusion

Using a novel and advanced tractography method to isolate major intrahemispheric white matter tracts in autism, this study has revealed that there are significant alterations in the microstructural organization of white matter in the IFOF in ASD. This altered organization of IFOF white matter is associated with poorer visuospatial processing performance, a finding that provides an insight into specific structural brain abnormalities that may influence atypical visuospatial processing in autism.

Acknowledgments

We wish to thank all the families who participated in this study, Mr. Sean Brennan and Dr. Miriam Law-Smith for help with recruitment, and Dr. Flavio Dell'Acqua, Dr. Marco Catani, Dr. Dara Cannon and Dr. Stephen Meredith for expert advice on setting up the study. We gratefully acknowledge the support of Molecular Medicine Ireland who funded this work (grant number 4AA-G04005-0-S06), and thank Mr. Brendan Behan, Mr. Sojo Joseph and many others for their invaluable assistance during the study.

References

Alexander, D.C., Barker, G.J., & Arridge, S.R. (2002). Detection and modeling of non-Gaussian apparent diffusion coefficient profiles in human brain data. Magnetic Resonance in Medicine, 48, 331–340.

Basser, P.J., Mattiello, J., & LeBihan, D. (1994). MR diffusion tensor spectroscopy and imaging. Biophysical Journal, 66, 259–267.

Behrens, T.E., Berg, H.J., Jbabdi, S., Rushworth, M.F., & Woolrich, M.W. (2007). Probabilistic diffusion tractography with multiple fibre orientations: What can we gain? NeuroImage, 34, 144–155.

Caron, M.J., Mottron, L., Berthiaume, C., & Dawson, M. (2006). Cognitive mechanisms, specificity and neural underpinnings of visuospatial peaks in autism. Brain, 129, 1789–1802.

Catani, M., Jones, D.K., Daly, E., Embiricos, N., Deeley, Q., et al. (2008). Altered cerebellar feedback projections in Asperger syndrome. NeuroImage, 41, 1184–1191.

Catani, M., & Mesulam, M. (2008). The arcuate fasciculus and the disconnection theme in language and aphasia: History and current state. Cortex, 44, 953–961.

Catani, M., & Thiebaut de Schotten, M. (2008). A diffusion tensor imaging tractography atlas for virtual in vivo dissections. Cortex, 44, 1105–1132.

Chang, L.C., Jones, D.K., & Pierpaoli, C. (2005). RESTORE: Robust estimation of tensors by outlier rejection. Magnetic Resonance in Medicine, 53, 1088–1095.

Conturo, T.E., Williams, D.L., Smith, C.D., Gultepe, E., Akbudak, E., & Minshew, N.J. (2008). Neuronal fiber pathway abnormalities in autism: An initial MRI diffusion tensor tracking study of hippocampo-fusiform and amygdalo-fusiform pathways. Journal of the International Neuropsychological Society, 14, 933–946.

Damarla, S.R., Keller, T.A., Kana, R.K., Cherkassky, V.L., Williams, D.L., et al. (2010). Cortical underconnectivity coupled with preserved visuospatial cognition in autism: Evidence from an fMRI study of an embedded figures task. Autism Research, 3, 273–279.

Dell'Acqua, F., Simmons, A., Williams, S.C., & Catani, M. (2012). Can spherical deconvolution provide more information than fiber orientations? Hindrance modulated orientational anisotropy, a true-tract specific index to characterize white matter diffusion. Human Brain Mapping (in press) doi: 10.1002/hbm.22080.

Doricchi, F., Thiebaut de Schotten, M., Tomaiuolo, F., & Bartolomeo, P. (2008). White matter (dis)connections and gray matter (dys)functions in visual neglect: Gaining insights into the brain networks of spatial awareness. Cortex, 44, 983–995.

Douaud, G., Jbabdi, S., Behrens, T.E., Menke, R.A., Gass, A., et al. (2011). DTI measures in crossing-fibre areas: Increased diffusion anisotropy reveals early white matter alteration in MCI and mild Alzheimer's disease. NeuroImage, 55, 880–890.

Epelbaum, S., Pinel, P., Gaillard, R., Delmaire, C., Perrin, M., et al. (2008). Pure alexia as a disconnection syndrome: New diffusion imaging evidence for an old concept. Cortex, 44, 962–974.

Fletcher, P.T., Whitaker, R.T., Tao, R., DuBray, M.B., Froehlich, A., et al. (2010). Microstructural connectivity of the arcuate fasciculus in adolescents with high-functioning autism. NeuroImage, 51, 1117–1125.

Fox, C.J., Iaria, G., & Barton, J.J. (2008). Disconnection in prosopagnosia and face processing. Cortex, 44, 996–1009.

Frank, L.R. (2002). Characterization of anisotropy in high angular resolution diffusion-weighted MRI. Magnetic Resonance in Medicine, 47, 1083–1099.

Happe, F., & Frith, U. (2006). The weak coherence account: Detail-focused cognitive style in autism spectrum disorders. Journal of Autism and Developmental Disorders, 36, 5–25.

Harms, M.B., Martin, A., & Wallace, G.L. (2010). Facial emotion recognition in autism spectrum disorders: A review of behavioral and neuroimaging studies. Neuropsychology Review, 20, 290–322.

Hong, S., Ke, X., Tang, T., Hang, Y., Chu, K., et al. (2011). Detecting abnormalities of corpus callosum connectivity in autism using magnetic resonance imaging and diffusion tensor tractography. Psychiatry Research, 194, 333–339.

Jeong, J.W., Kumar, A.K., Sundaram, S.K., Chugani, H.T., & Chugani, D.C. (2011). Sharp curvature of frontal lobe white matter pathways in children with autism spectrum disorders: Tract-based morphometry analysis. AJNR. American Journal of Neuroradiology, 32, 1600–1606.

Jeurissen, B., Leemans, A., Jones, D.K., Tournier, J.D., & Sijbers, J. (2011). Probabilistic fiber tracking using the residual bootstrap with constrained spherical deconvolution. Human Brain Mapping, 32, 461–479.

Jeurissen, B., Leemans, A., Tournier, J.D., Jones, D.K., & Sijbers, J. (2012). Investigating the prevalence of complex fiber configurations in white matter tissue with diffusion MRI. Human Brain Mapping (in press) doi:10.1002/hbm.22099.

Jones, D.K., & Cercignani, M. (2010). Twenty-five pitfalls in the analysis of diffusion MRI data. NMR in Biomedicine, 23, 803–820.

Jones, D.K., & Leemans, A. (2011). Diffusion tensor imaging. Methods in Molecular Biology, 711, 127–144.

Jou, R.J., Jackowski, A.P., Papademetris, X., Rajeevan, N., Staib, L.H., & Volkmar, F.R. (2011). Diffusion tensor imaging in autism spectrum disorders: Preliminary evidence of abnormal neural connectivity. The Australian and New Zealand Journal of Psychiatry, 45, 153–162.

Just, M., Cherkassky, V., Keller, T., & Minshew, N. (2004). Cortical activation and synchronization during sentence comprehension in high-functioning autism: Evidence of underconnectivity. Brain, 127(Pt 8), 1811–1821.

Just, M.A., Cherkassky, V.L., Keller, T.A., Kana, R.K., & Minshew, N.J. (2007). Functional and anatomical cortical underconnectivity in autism: Evidence from an FMRI study of an executive function task and corpus callosum morphometry. Cereb Cortex, 17, 951–961.

Klein, S., Staring, M., Murphy, K., Viergever, M.A., & Pluim, J.P. (2010). Elastix: A toolbox for intensity-based medical image registration. IEEE Transactions on Medical Imaging, 29, 196–205.

Kumar, A., Sundaram, S.K., Sivaswamy, L., Behen, M.E., Makki, M.I., et al. (2010). Alterations in frontal lobe tracts and corpus callosum in young children with autism spectrum disorder. Cereb Cortex, 20, 2103–2113.

Langen, M., Leemans, A., Johnston, P., Ecker, C., Daly, E., et al. (2012). Fronto-striatal circuitry and inhibitory control in autism: Findings from diffusion tensor imaging tractography. Cortex, 48, 183–193.

Lee, P.S., Foss-Feig, J., Henderson, J.G., Kenworthy, L.E., Gilotty, L., et al. (2007). Atypical neural substrates of Embedded Figures Task performance in children with Autism Spectrum Disorder. NeuroImage, 38, 184–193.

Leemans, A., Jeurissen, B., Sijbers, J., & Jones, D.K. (2009). ExploreDTI: A graphical toolbox for processing, analyzing, and visualizing diffusion MR data. Proceedings of the 17th Annual Meeting of International Society for Magnetic Resonance in Medicine, Hawaii, USA, 3536.

Leemans, A., & Jones, D.K. (2009). The B-matrix must be rotated when correcting for subject motion in DTI data. Magnetic Resonance in Medicine, 61, 1336–1349.

Liu, Y., Cherkassky, V.L., Minshew, N.J., & Just, M.A. (2011). Autonomy of lower-level perception from global processing in autism: Evidence from brain activation and functional connectivity. Neuropsychologia, 49, 2105–2111.

Lo, Y.C., Soong, W.T., Gau, S.S., Wu, Y.Y., Lai, M.C., et al. (2011). The loss of asymmetry and reduced interhemispheric connectivity in adolescents with autism: A study using diffusion spectrum imaging tractography. Psychiatry Research, 192, 60–66.

Lord, C., Risi, S., Lambrecht, L., Cook, E.H. Jr, Leventhal, B.L., et al. (2000). The autism diagnostic observation schedule-generic: A standard measure of social and communication deficits associated with the spectrum of autism. Journal of Autism and Developmental Disorders, 30, 205–223.

Lord, C., Rutter, M., & Le Couteur, A. (1994). Autism Diagnostic Interview-Revised: A revised version of a diagnostic interview for caregivers of individuals with possible pervasive developmental disorders. Journal of Autism and Developmental Disorders, 24, 659–685.

Manjaly, Z., Bruning, N., Neufang, S., Stephan, K., Brieber, S., et al. (2007). Neurophysiological correlates of relatively enhanced local visual search in autistic adolescents. NeuroImage, 35, 283–291.

Martino, J., Brogna, C., Robles, S.G., Vergani, F., & Duffau, H. (2010). Anatomic dissection of the inferior fronto-occipital fasciculus revisited in the lights of brain stimulation data. Cortex, 46, 691–699.

McGrath, J., Johnson, K., Ecker, C., O'Hanlon, E., Gill, M., et al. (2012). Atypical visuospatial processing in autism: Insights from functional connectivity analysis. Autism Research 5, 314–330.

Metzler-Baddeley, C.M., Hunt, S., Jones, D.K., Leemans, A., Aggleton, J.P., & O'Sullivan, M.J. (2012). Temporal association tracts and the breakdown of episodic memory in mild cognitive impairment. Neurology 79, 2233–2240.

Monk, C.S., Peltier, S.J., Wiggins, J.L., Weng, S.-J., Carrasco, M., et al. (2009). Abnormalities of intrinsic functional connectivity in autism spectrum disorders. NeuroImage, 47, 764–772.

Mori, S., Kaufmann, W.E., Davatzikos, C., Stieltjes, B., Amodei, L., et al. (2002). Imaging cortical association tracts in the human brain using diffusion-tensor-based axonal tracking. Magnetic Resonance in Medicine, 47, 215–223.

Mori, S., & van Zijl, P.C. (2002). Fiber tracking: Principles and strategies—a technical review. NMR in Biomedicine, 15, 468–480.

Mottron, L., Dawson, M., Soulières, I., Hubert, B., & Burack, J. (2006). Enhanced perceptual functioning in autism: An update, and eight principles of autistic perception. Journal of Autism and Developmental Disorders, 36, 27–43.

Philippi, C.L., Mehta, S., Grabowski, T., Adolphs, R., & Rudrauf, D. (2009). Damage to association fiber tracts impairs recognition of the facial expression of emotion. Journal of Neuroscience, 29, 15089–15099.

Pierpaoli, C., Barnett, A., Pajevic, S., Chen, R., Penix, L.R., et al. (2001). Water diffusion changes in Wallerian degeneration and their dependence on white matter architecture. NeuroImage, 13(6 Pt 1), 1174–1185.

Pluim, J.P., Maintz, J.B., & Viergever, M.A. (2003). Mutual-information-based registration of medical images: A survey. IEEE Transactions on Medical Imaging, 22, 986–1004.

Poustka, L., Jennen-Steinmetz, C., Henze, R., Vomstein, K., Haffner, J., & Sieltjes, B. (2011). Fronto-temporal disconnectivity and symptom severity in children with autism spectrum disorder. The World Journal of Biological Psychiatry, 13, 269–280.

Pruessmann, K.P., Weiger, M., Scheidegger, M.B., & Boesiger, P. (1999). SENSE: Sensitivity encoding for fast MRI. Magnetic Resonance in Medicine, 42, 952–962.

Pugliese, L., Catani, M., Ameis, S., Dell'Acqua, F., de Schotten, M.T., et al. (2009). The anatomy of extended limbic pathways in Asperger syndrome: A preliminary diffusion tensor imaging tractography study. NeuroImage, 47, 427–434.

Raffelt, D., Tournier, J.D., Rose, S., Ridgway, G.R., Henderson, R., et al. (2012). Apparent Fibre Density: A novel measure for the analysis of diffusion-weighted magnetic resonance images. NeuroImage, 59, 3976–3994.

Reijmer, Y.D., Leemans, A., Heringa, S.M., Wielaard, I., Jeurissen, B., et al. (2012). Improved sensitivity to cerebral white matter abnormalities in Alzheimer's disease with spherical deconvolution based tractography. PLoS ONE 7, e44074.

Robertson, L.C., & Ivry, R. (2000). Hemispheric asymmetries: Attention to visual and auditory primitives. Current Directions in Psychological Science, 9, 59–63.

Rudrauf, D., Mehta, S., & Grabowski, T.J. (2008). Disconnection's renaissance takes shape: Formal incorporation in group-level lesion studies. Cortex, 44, 1084–1096.

Sahyoun, C.P., Belliveau, J.W., Soulieres, I., Schwartz, S., & Mody, M. (2010). Neuroimaging of the functional and structural networks underlying visuospatial vs. linguistic reasoning in high-functioning autism. Neuropsychologia, 48, 86–95.

Soulieres, I., Zeffiro, T.A., Girard, M.L., & Mottron, L. (2011). Enhanced mental image mapping in autism. Neuropsychologia, 49, 848–857.

Thiebaut de Schotten, M., Kinkingnehun, S., Delmaire, C., Lehericy, S., Duffau, H., et al. (2008). Visualization of disconnection syndromes in humans. Cortex, 44, 1097–1103.

Thomas, C., Humphreys, K., Jung, K.J., Minshew, N., & Behrmann, M. (2011). The anatomy of the callosal and visual-association pathways in high-functioning autism: A DTI tractography study. Cortex, 47, 863–873.

Tournier, J.D., Calamante, F., & Connelly, A. (2007). Robust determination of the fibre orientation distribution in diffusion MRI: Non-negativity constrained super-resolved spherical deconvolution. NeuroImage, 35, 1459–1472.

Tournier, J.D., Calamante, F., Gadian, D.G., & Connelly, A. (2004). Direct estimation of the fiber orientation density function from diffusion-weighted MRI data using spherical deconvolution. NeuroImage, 23, 1176–1185.

Tournier, J.D., Mori, S., & Leemans, A. (2011). Diffusion tensor imaging and beyond. Magnetic Resonance in Medicine, 65, 1532–1556.

Tournier, J.D., Yeh, C.H., Calamante, F., Cho, K.H., Connelly, A., & Lin, C.P. (2008). Resolving crossing fibres using constrained spherical deconvolution: Validation using diffusion-weighted imaging phantom data. NeuroImage, 42, 617–625.

Verhoeven, J.S., Rommel, N., Prodi, E., Leemans, A., Zink, I., et al. (2011). Is there a common neuroanatomical substrate of language deficit between autism spectrum disorder and specific language impairment? Cerebral Cortex 22, 2263–2271.

Vos, S.B., Jones, D.K., Jeurissen, B., Viergever, M.A., & Leemans, A. (2012). The influence of complex white matter architecture on the mean diffusivity in diffusion tensor MRI of the human brain. NeuroImage, 59, 2208–2216.

Vos, S.B., Jones, D.K., Viergever, M.A., & Leemans, A. (2011). Partial volume effect as a hidden covariate in DTI analyses. NeuroImage, 55, 1566–1576.

Wakana, S., Caprihan, A., Panzenboeck, M.M., Fallon, J.H., Perry, M., et al. (2007). Reproducibility of quantitative tractography methods applied to cerebral white matter. NeuroImage, 36, 630–644.

Wan, C.Y., Marchina, S., Norton, A., & Schlaug, G. (2012). Atypical hemispheric asymmetry in the arcuate fasciculus of completely nonverbal children with autism. Annals of the New York Academy of Sciences, 1252, 332–337.

Wechsler, D. (1997). WAIS-III administration and scoring manual. San Antonio, TX: Psychological Corporation.

Wechsler, D. (2004). The Wechsler intelligence scale for children, fourth ed. London: Pearson Assessment.

Wedeen, V.J., Reese, T.G., Tuch, D.S., Weigel, M.R., Dou, R.M., et al. (2000). Mapping fibre orientation spectra in cerebral white matter with Fourier-transform diffusion MRI. Paper presented at the International Society of Magnetic Resonance in Medicine.

Wedeen, V.J., Rosene, D.L., Wang, R., Dai, G., Mortazavi, F., et al. (2012). The geometric structure of the brain fiber pathways. Science, 335, 1628–1634.

Wedeen, V.J., Wang, R.P., Schmahmann, J.D., Benner, T., Tseng, W.Y., et al. (2008). Diffusion spectrum magnetic resonance-imaging (DSI) tractography of crossing fibers. NeuroImage, 41, 1267–1277.

Weinstein, M., Ben-Sira, L., Levy, Y., Zachor, D.A., Itzhak, E.B., et al. (2011). Abnormal white matter integrity in young children with autism. Human Brain Mapping, 32, 534–543.

Westin, C.F., Maier, S.E., Mamata, H., Nabavi, A., Jolesz, F.A., & Kikinis, R. (2002). Processing and visualization for diffusion tensor MRI. Medical Image Analysis, 6, 93–108.

Wheeler-Kingshott, C.A., & Cercignani, M. (2009). About "axial" and "radial" diffusivities. Magnetic Resonance in Medicine, 61, 1255–1260.

Wolff, J.J., Gu, H., Gerig, G., Elison, J.T., Styner, M., et al. (2012). Differences in white matter fiber tract development present from 6 to 24 months in infants with autism. The American Journal of Psychiatry, 169, 589–600.

Yovel, G., Levy, J., & Yovel, I. (2001). Hemispheric asymmetries for global and local visual perception: Effects of stimulus and task factors. Journal of Experimental Psychology. Human Perception and Performance, 27, 1369–1385.